Pain Physician 2018; 21:E501-E508 • ISSN 2150-1149

Case-Control Study

Comparison of 3 Approaches to Percutaneous Epidural Adhesiolysis and Neuroplasty in Post Lumbar Surgery Syndrome

Mert Akbas, MD[1], Abdel Reheem Elawamy, MD[2], Haitham Hamdy Salem, MD[3], Ahmed Zaghloul Fouad, MD[4], Nisreen Adel Abbas, MD[4], and Gozde Dagistan, MD[1]

From: [1]Algology Division, Department of Anesthesia, Akdeniz University, Antalya, Turkey; [2]Department of Anesthesia, Assiut University, Assiut, Egypt; [3]Department of Neurology, Ain Shams University, Cairo, Egypt; [4]Department of Radiology, Cairo University, Cairo, Egypt

Address Correspondence: Haitham Hamdy Salem, MD Department of Neurology, 2nd Floor, Ain Shams University Hospitals, Abbassia, Cairo, Egypt E-mail: haithamhamdy@yahoo.com

Disclaimer: There was no external funding in the preparation of this manuscript. Conflict of interest: Each author certifies that he or she, or a member of his or her immediate family, has no commercial association (i.e., consultancies, stock ownership, equity interest, patent/licensing arrangements, etc.) that might pose a conflict of interest in connection with the submitted manuscript.

Manuscript received: 10-02-2017
Revised manuscript received: 03-22-2018
Accepted for publication: 04-11-2018

Free full manuscript: www.painphysicianjournal.com

Background: Percutaneous epidural adhesiolysis and neuroplasty (PEAN) has been proven to be safe and effective in treating different spine pathologies, in particular post lumbar surgery syndrome (PLSS).

Objectives: The purpose of this study was to compare the efficacy and complication rates of the 3 different PEAN anatomical approaches (caudal, S1 foraminal, and L5-S1 transforaminal) used to treat PLSS.

Study Design: This study used a case control, blind study.

Setting: The research took place at the pain clinic and interventional pain practice room at Asyut University Hospital, Assiut, Egypt.

Methods: Sixty consecutive PLSS patients were recruited and randomized into 3 groups (caudal, S1 foraminal, and L5-S1 transforaminal) before receiving adhesiolysis and neuroplasty. All patients underwent nerve conduction studies and magnetic resonance imaging (MRI). Pain severity levels were assessed and measured using the Oswestry Disability Questionnaire (OSW) and the Visual Analog Scale (VAS). Patient satisfaction was evaluated using a Likert scale. The first assessment was performed prior to the procedure to determine the patients' baseline levels of pain severity. Follow-up assessments were performed 1-, 3-, and 6-months after the procedure.

Results: Results of the group pairwise analysis indicated that, relative to baseline, there were significant decreases in pain relief scores (VAS and OWS) and functional assessment expressed by patients' satisfaction across all time intervals and in all 3 groups ($P < 0.01$). Conversely, a between group analysis revealed that VAS, OWS, and patient satisfaction scores were comparable across the 3 groups at all time intervals ($P > 0.05$). There were no differences in rates of complications between the 3 different groups.

Limitations: Our study was limited by the low number of patients and the short duration (6 months) of follow-up.

Conclusion: The 3 anatomical approaches (caudal, S1 foraminal, and L5-S1 transforaminal) result in the same outcome with regard to pain relief and complication rate.

Key words: Post lumber surgery syndrome, post laminectomy back pain, percutaneous adhesiolysis, Racz catheter, percutaneous neuroplasty

Pain Physician 2018: 21:E501-E508

Post lumbar surgery syndrome (PLSS) is characterized clinically by persistent or recurrent axial or lower extremity pain, even after anatomically successful spinal surgery (1,2). Occurrence rates range between 10-40% (3). PLSS is presumed to occur secondary to many causes. There is strong

evidence, however, that the postoperative epidural or perineural adhesions and scarring that can develop after surgery is a main causal factor, accounting for approximately 20-36% of cases (4,5).

PLSS management is considered a challenge, as conservative medical and physical therapies or repeated back surgery often provide inadequate pain relief (6). PLSS cases with poor response to conservative management are often treated with epidural steroid injections (7). However, epidural steroid injections frequently produce disappointing results as a result of the surgically-induced fibrosis and adhesions that impede injected material from spreading effectively into the target area (8).

Percutaneous epidural adhesiolysis and neuroplasty (PEAN), also known as Racz neurolysis, is a minimally interventional procedure developed by Racz and Holubec in 1989 (9). The procedure has been proven to be safe and effective in treating different spine pathologies such as post laminectomy syndrome, epidural adhesions, vertebral body compression fractures, disc disruption, and radiculopathy (10).

Available systematic reviews have reached different conclusions about the efficacy of PEAN in managing lumbar PLSS (11-16). The aim of this study was to determine the efficacy as well as the complication rates of all 3 different PEAN anatomical approaches (caudal, S1 foraminal, and L5-S1 transforaminal) in treating lumbar PLSS.

Methods

Patients

Between June 2013 and September 2016, we identified 60 consecutive PLSS patients (age >18 years) visiting our pain clinic at Asyut University Hospital, Asyut, Egypt. All patients gave informed consent. This was a pilot study to test whether or not there was a difference in outcome and complications between the 3 PEAN anatomical approaches. The study was approved by the Asyut University Local Research Ethics Committee. All patients underwent nerve conduction studies and lumbosacral magnetic resonance imaging (MRI).

Inclusion Criteria

Patients were eligible to participate in the study if the following inclusion criteria were met: (a) over the age of 18 years; (b) history of L5-S1 lumbar spine surgery; (c) history of persistent function-limiting lower extremity pain aggravated by "dural tug" (17) (observed when the patient, sitting on the exam table with legs stretched out, bends forward, bringing on the back pain), with or without low back pain of at least 6 months duration after failure of conventional conservative management in most patients including NSAIDS, muscle relaxants (tizanidine, magnesium sulphate) and pregabalin. All patients received medical therapy and physiotherapy for at least 4 weeks.

Exclusion Criteria

Patients were not eligible to participate in the study if they met any of the following exclusion criteria: (a) more than 60 years of age; (b) uncontrolled psychiatric disorders; (c) medical history that could prevent or interfere with the procedure, such as pregnancy or lactation, bleeding disorders, sepsis, infection at the skin puncture area, discitis, implanted artificial instruments, inability to lie in the prone position, or patient refusal or allergy to local anesthetics.

Randomization and Allocation Concealment

From a total sample of 60 patients, 20 were randomly assigned to each of the 3 groups (caudal, S1 foraminal, and L5-S1 transforaminal) by computer generated random allocation sequence. The operating room nurse, patients, and those collecting data on pain and satisfaction were blinded to patients' group assignment. The doctors administering the interventions were not blinded to the technique used, but were blinded to the process used to determine group assignment and were not involved in patient selection.

MRI Image analysis

Two experienced readers (NAA and HHS) visually analyzed the MRIs for the presence/absence of specific findings as shown in Table 1, namely: disc herniation, arachnoiditis, epidural fibrosis, canal stenosis, and degenerative changes. Inter- and intra-observer agreement for the presence/absence of different MRI findings (κ = 0.9 and 0.91, $P < .01$, respectively).

Procedures

All procedures were performed under fluoroscopy in a sterile operating room equipped to monitor patients' vital data. Patients were placed in prone position followed by sterilization and draping. A specially designed 16-gauge RX Coude® needle and a Racz®-catheter (Epimed International Inc., Johnstown, NY) were used for each of the 3 approaches. All patients were instructed to perform postprocedural exercises

– "neural flossing" – 3 to 4 times daily for 3 months to stretch the nerve root, thereby adding mechanical traction after the epidural hydrostatic lysis.

Caudal Approach (20 patients)

After identifying the sacral hiatus with lateral fluoroscopic guidance, a skin wheal was raised with a local anesthetic, positioned 1 inch lateral and 2 inches caudal to the sacral hiatus on the side opposite the documented radiculopathy. The skin was nicked and a 16-gauge RX Coudé® epidural needle inserted into the caudal canal below the level of the S3 foramen. An epidurogram was performed using 10 mL of omnipaque after negative aspiration. Under continuous anteroposterior (AP) fluoroscopic guidance, the tip of the catheter was advanced toward the ventral lateral epidural space at the desired level (Fig. 1). Under real-time fluoroscopy, 2-3 mL of additional contrast was injected through the catheter to outline the "scarred in" nerve root; this was followed by a slow injection of 1500 U of hyaluronidase. A 3 mL test dose of a 10 mL local anesthetic/steroid solution of 1% lidocaine and 80 mg of methylprednisolone (Depo-Medrol) was then given. If there was no evidence of intrathecal or intravascular injection, the remaining 7 mL was injected. The needle and catheter were removed together under continuous fluoroscopic guidance, the skin puncture site coated with antimicrobial ointment, the sterile dressing applied, and the patient transported to the recovery area.

Transforaminal L5 Approach (20 patients)

Once the target level was identified using an AP fluoroscopic image, the superior endplate of the sacrum was squared. The fluoroscope was then obliqued and rotated for the best visualization of the superior articular process (SAP). A skin wheal with local anesthetic was raised slightly lateral to the shadow of the tip of the SAP. Using the gun-barrel technique, a 16-gauge RX Coudé® needle was advanced toward the tip of the SAP until the tip contacted bone. The tip of the needle was rotated 180 degrees laterally and advanced about 5 mm, then rotated back medially 180 degrees. The needle was advanced slowly until a clear "pop" was felt as the needle penetrated the intertransverse ligament. In the lateral fluoroscopic image, the tip of the needle was positioned just past the SAP in the posterior foramen. The catheter was slowly inserted into the foramen and advanced until the tip was just short of the middle of the spinal canal in the AP image, and into the anterior epidural space in the lateral image. To confirm epidural spread, 1-2 mL of contrast was injected, followed by hyaluronic acid and steroid, as in the caudal approach.

S1 Approach (20 patients)

After the target level was identified with an AP fluoroscopic image, the C-arm was inclined cephalocaudally until the anterior and posterior S1 foramen were superimposed upon each other. The fluoroscope was then obliquely rotated approximately 15 degrees to the side of the radiculopathy. A skin wheal was raised with local anesthetic at the lateral part of the foramen. Using the gun-barrel technique, the skin was pierced with a 16-gauge RX Coudé® needle and advanced toward the foramen until the tip of the needle was just past the posterior foramen. In the AP view under continuous AP fluoroscopy, the catheter was slowly inserted into the foramen and advanced until the tip was just short of the middle of the spinal canal in the AP image, and into the anterior epidural space in the lateral image (Fig. 1). To confirm epidural spread, 1-2 mL of contrast was injected, followed by hyaluronic acid and steroid, as in the caudal approach.

Outcome Assessment

Pain severity levels were measured with the Oswestry Disability Questionnaire (OSW) and the Visual Analog Scale (VAS). Patient satisfaction was evaluated using a Likert-type scale. The first assessment was performed prior to the procedure to establish the patients' baseline. Follow-up assessments were performed 1-, 3-, and 6-months after the procedure to assess the extent to which improvement was maintained.

Data Analysis

Analysis was done in SPSS Version 22 (IBM Corporation, Armonk, NY) using 1-way ANOVA for continuous outcome variables, the Pearson correlation coefficient, and the χ^2 test for dichotomous outcome variables.

Results

General Characteristics

A total of 60 consecutive patients were identified and randomly recruited into the study. Most of our studied population (48 patients, 80%) had undergone a single back surgery. Radiculopathy was the most common finding from nerve conduction studies, evident in 45 (75%) patients. MRI findings showed epidural fibrosis in 16 (27%) patients. There were no significant differences in demographic and general characteristics

between the 3 studied groups (all $P > 0.05$). Other patient characteristics are shown in Table 1.

Rate of Complications

None of the studied patients developed any drug reactions. There were no major adverse events in any of the 3 groups. The rate of complications did not differ between the 3 approaches ($P > 0.05$); however, a higher number of patients (4) in the S1 foraminal approach experienced adverse events compared to patients in the caudal (3) and L5-S1 transforaminal (2) groups. The rate and type of complications for each group are shown in Fig. 2.

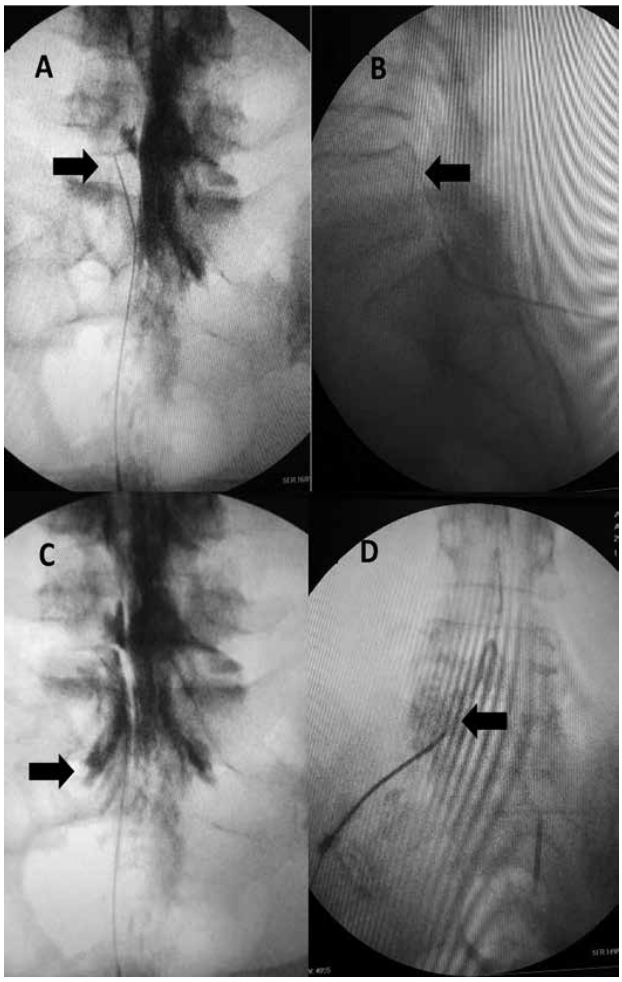

Fig. 1. *Fluoroscopic images. (A) Antero-posterior view of caudal approach showing the catheter placed at the target level with filling defect at left L5 root (arrow). (B) Lateral view of caudal approach showing the catheter in the anterior epidural space (arrow). (C) Antero-posterior view of caudal approach with flow of contract medium at left L5 (arrow) after the procedure. (D) Antero-posterior view of S1 approach showing the tip of the catheter just short of the middle of the spinal canal (arrow).*

Outcomes

Results of the group pairwise analysis indicated that, relative to baseline, there were significant decreases in pain relief scores (VAS and OWS) and functional assessment expressed by patients' satisfaction across all time intervals and in all 3 groups ($P < 0.01$), as shown in Table 2. Conversely, a between-group analysis revealed that VAS, OWS , and patient satisfaction scores were comparable across the 3 groups at all time intervals ($P > 0.05$), as shown in Fig. 3.

Discussion

PEAN has been used in interventional pain management to treat patients with chronic, refractory low back and lower extremity pain following lumbar surgery; its purpose is root hydrodissection, elimination of scar tissue, and assurance of the delivery of high concentrations of injected drugs to targeted areas (18,19). Many studies have proven the efficiency of PEAN – mainly the caudal approach – in managing refractory back/leg pain following PLSS (9,20-24). Similarly, our study has shown that, using any of the 3 approaches, PEAN is effective in improving patient satisfaction and pain relief, evidenced by significant decreases in pain scores ($P < 0.01$).

Although patients were selected for this study based on the presence of function-limiting pain potentially attributable to multiple factors, MRI results indicated that 27% of patients had evidence of epidural fibrosis (considered a low rate). Even in the absence of fibrosis, however, PEAN has been shown to be beneficial (24-26).

In our study, there were no statistically significant differences between the 3 anatomical approaches ($P < 0.05$) in patients

Table 1. *General characteristics of the study population.*

	Caudal (n = 20)	S1 Foraminal (n = 20)	L5 Transforaminal (n = 20)	Total (n = 60)
Gender				
Men	14 (70%)	13 (65%)	14 (70%)	41 (68.3%)
Women	6 (30%)	7 (35%)	6 (30%)	19 (31.7%)
Age	41.4 ± 16.1	43 ± 12.5	38.8 ± 14.5	41.1 ± 14.3
Weight	81.7 ± 11.7	78.3 ± 10.8	78.3 ± 10.7	79.4 ± 10.9
Number of Back Surgeries				
1	15 (75%)	17 (85%)	16 (80%)	48 (80%)
2	3 (15%)	2 (10%)	2 (10%)	7 (11.7%)
More than 2	2 (10%)	1 (5%)	2 (10%)	5 (8.3%)
Lumbosacral MRI				
Nonspecific	7 (35%)	10 (50%)	9 (45%)	26 (43%)
Epidural fibrosis	5 (25%)	5 (25%)	6 (30%)	16 (27%)
Recurrent disc herniation	3 (15%)	1 (5%)	2 (10%)	6 (10%)
Orchiditis	0 (0%)	1 (5%)	0 (0%)	1 (0.017%)
Degenerative changes	1 (5%)	0 (0%)	0 (0%)	1 (0.017%)
Spinal canal stenosis	0 (0%)	1 (5%)	1 (5%)	2 (0.03%)
Combination of more than one	4 (20%)	2 (10%)	2 (10%)	8 (13.3%)
Lumbosacral x-ray				
Nonspecific	6 (30%)	2 (10%)	2 (10%)	10 (16.7%)
Spondylo-degenerative	11 (55%)	14 (70%)	15 (75%)	40 (66.7%)
Instability	3 (15%)	3 (15%)	2 (10%)	8 (13.3%)
Other findings	0 (0%)	1 (5%)	1 (5%)	2 (3.3%)
Nerve Conduction Studies				
Free	1 (5%)	0 (0%)	0 (0%)	1 (1.7%)
Radiculopathy	14 (70%)	15 (75%)	16 (80%)	45 (75%)
Peripheral neuropathic	4 (20%)	3 (15%)	3 (15%)	10 (16.6%)
Other Findings	1 (5%)	2 (10%)	1 (5%)	4 (6.7%)

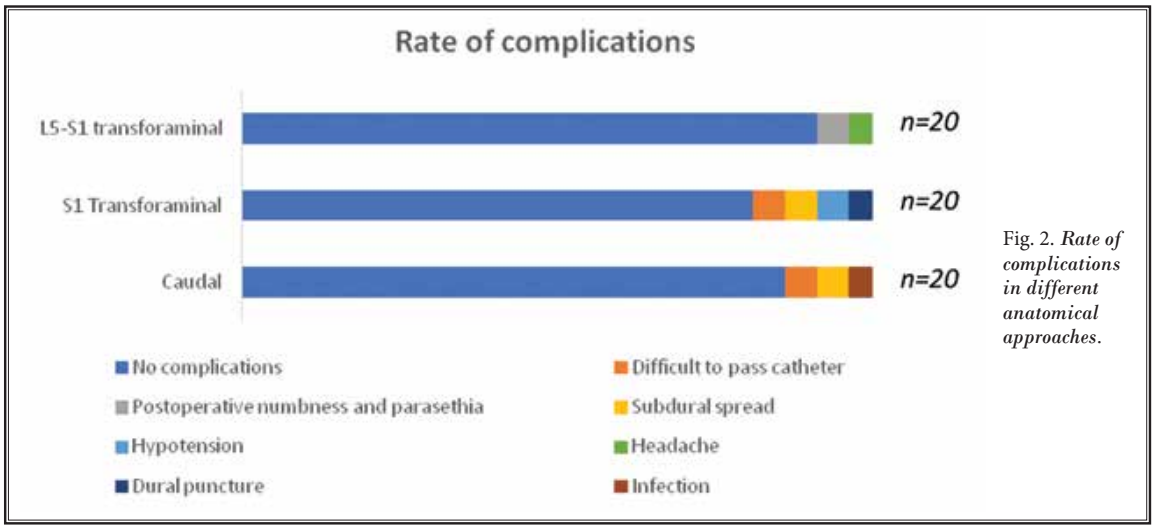

Fig. 2. *Rate of complications in different anatomical approaches.*

Table 2. *Pain relief and patient satisfaction scores before and after procedures.*

	Caudal (n = 20)	S1 Transforaminal (n = 20)	L5-S1 Transforaminal (n = 20)
VAS			
Before procedure	8.55 ± 0.18	8.40 ± 0.21	8.55 ± 0.21
1 mo after procedure	2.65 ± 0.50	2.40 ± 0.35	2.80 ± 0.45
3 mos after procedure	3.50 ± 0.58	3.00 ± 0.42	3.80 ± 0.57
6 mos after procedure	4.00 ± 0.59	3.70 ± 0.47	4.20 ± 0.55
OWS			
Before procedure	3.55 ± 0.11	3.55 ± 0.11	3.60 ± 0.11
1 mo after procedure	1.70 ± 0.18	1.65 ± 0.18	1.85 ± 0.19
3 mos after procedure	1.90 ± 0.25	1.65 ± 0.18	2.05 ± 0.26
6 mos after procedure	2.00 ± 0.25	1.85 ± 0.19	2.15 ± 0.25
Patient Satisfaction			
1 mo after procedure	3.30 ± 0.26	3.40 ± 0.23	3.50 ± 0.19
3 mos after procedure	3.20 ± 0.28	3.40 ± 0.19	3.10 ± 0.25
6 mos after procedure	3.05 ± 0.27	3.25 ± 0.22	2.95 ± 0.25

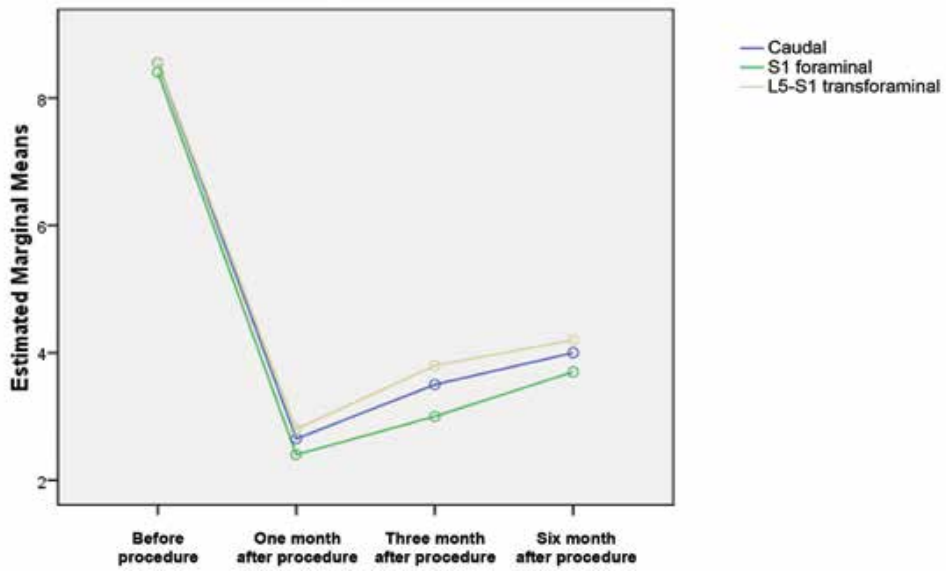

Fig. 3. *Pain relief in the 3 anatomical procedures (a between-group analysis).*

with PLSS at the L5-S1 level. To our knowledge, there have been no other studies to date comparing different anatomical approaches used in PEAN. Manchikanti et al (27), however, found similar efficacy across different anatomical approaches (caudal, interlaminar, and transforaminal) used in epidural injections of steroids and local anesthetics for managing chronic pain and disability from disc herniation.

Regarding the incidence of adverse events, our study showed that all of the 3 approaches can be con-

sidered safe with low complication rates. There were no statistically significant differences in complication rates between the 3 anatomical approaches ($P > 0.05$). These results are similar to those of previous randomized trials (27,28). Although the S1 foraminal approach showed a higher number of complications compared to the caudal and L5-S1 transforaminal approaches, this could be attributed to the novelty of the S1 approach and the need for more physician training and practice.

Our study was limited by the number of patients and would benefit from a larger sample. The period of follow-up to assess pain relief and patient satisfaction was limited to 6 months, and a longer follow-up period would be favorable in confirming the results.

Conclusion

This study suggests that the 3 anatomical approaches (caudal, S1 foraminal, and L5-S1 transforaminal) used in PEAN have the same pain relief outcomes and complication rates. If confirmed in other studies, this will have important implications for the management of patients with post lumbar surgery syndrome.

References

1. Van Buyten JP. Neurostimulation for chronic neuropathic back pain in failed back surgery syndrome. *J Pain Symptom Manage* 2006; 4:S25-S29.
2. Thomson S. Failed back surgery syndrome – definition, epidemiology and demographics. *Br J Pain* 2013; 7:56-59.
3. Chan CW, Peng P. Failed back surgery syndrome. *Pain Med* 2011; 12:577-606.
4. Epter RS, Helm S II, Hayek SM, Benyamin RM, Smith HS, Abdi S. Systematic review of percutaneous adhesiolysis and management of chronic low back pain in post lumbar surgery syndrome. *Pain Physician* 2009; 12:361-378.
5. Ross JS, Robertson JT, Frederickson RC, Petrie JL, Obuchowski N, Modic MT, deTribolet N. Association between peridural scar and recurrent radicular pain after lumbar discectomy: Magnetic resonance evaluation. *Neurosurg* 1996; 38:855-863.
6. Hagen KB, Jamtvedt G, Hilds G, Winnem MF. The updated Cochrane review of bed rest for low back pain and sciatica. *Spine* 2005; 30:542-546.
7. Shah RV, Merritt W, Collins D, Racz GB. Targeting the spinal nerve via a double-needle, transforaminal approach in failed back surgery syndrome: Demonstration of a technique. *Pain Physician* 2004; 7:93-97.
8. Devulder J, Deene P, De Laat M, Van Bastelaere M, Brusselmans G, Rolly G. Nerve root sleeve injections in patients with failed back surgery syndrome: A comparison of three solutions. *Clin J Pain* 1999; 15:132-135.
9. Racz GB, Holubec JT. Lysis of adhesions in the epidural space. In: Racz GB (ed). *Techniques of Neurolysis.* Springer, Boston, MA, 1989, pp 57-72. *Current Management of Pain*, vol 4.
10. Manchikanti L, Bakhit CE. Percutaneous lysis of epidural adhesions. *Pain Physician* 2000; 3:46-64.
11. Manchikanti L, Abdi S, Atluri S, Benyamin RM, Boswell MV, Buenaventura RM, Bryce DA, Burks PA, Caraway DL, Calodney AK, Cash KA, Christo PJ, Cohen SP, Colson J, Conn A, Cordner H, Coubarous S, Datta S, Deer TR, Diwan S, Falco FJ, Fellows B, Geffert S, Grider JS, Gupta S, Hameed H, Hameed M, Hansen H, Helm S 2nd, Janata JW, Justiz R, Kaye AD, Lee M, Manchikanti KN, McManus CD, Onyewu O, Parr AT, Patel VB, Racz GB, Sehgal N, Sharma ML, Simopoulos TT, Singh V, Smith HS, Snook LT, Swicegood JR, Vallejo R, Ward SP, Wargo BW, Zhu J, Hirsch JA. An update of comprehensive evidence-based guidelines for interventional techniques in chronic spinal pain. Part II: Guidance and recommendations. *Pain Physician* 2013; 16:S49-S283.
12. Jamison DE, Hsu E, Cohen SP. Epidural adhesiolysis: An evidence-based review. *J Neurosurg Sci* 2014; 58:65-76.
13. Manchikanti L, Datta S, Gupta S, Munglani R, Bryce DA, Ward SP, Benyamin RM, Sharma ML, Helm S 2nd, Fellows B, Hirsch JA. A critical review of the American Pain Society clinical practice guidelines for interventional techniques: Part 2. Therapeutic interventions. *Pain Physician* 2010; 13:E215-E264.
14. Helm S II, Benyamin RM, Chopra P, Deer TR, Justiz R. Percutaneous adhesiolysis in the management of chronic low back pain in post lumbar surgery syndrome and spinal stenosis: A systematic review. *Pain Physician* 2012; 15:E435-E462.
15. Helm S II, Hayek SM, Colson J, Chopra P, Deer TR, Justiz R, Hameed M, Falco FJ. Spinal endoscopic adhesiolysis in post lumbar surgery syndrome: An update of assessment of the evidence. *Pain Physician* 2013; 16:SE125-SE150.
16. Lee F, Jamison DE, Hurley RW, Cohen SP. Epidural lysis of adhesions. *Korean J Pain* 2014; 27:3-15.
17. Racz GB, Heavner JE, Noe CE, Al-Kaisy A, Matsumoto T, Lee SC, Nagy L. Epidural lysis of adhesions and percutaneous neuroplasty. In: Racz GB, Noe CE (eds). *Techniques of Neurolysis.* 2nd ed. Springer, Boston, MA, 2016, pp 119-143.
18. Huntoon MA, Burgher AH. Back to the future: The end of the steroid century? *Pain Physician* 2008; 11:713-716.
19. Veihelmann A, Devens C, Trouiller H, Birkenmaier C, Gerdesmeyer L, Refior HJ. Epidural neuroplasty versus physiotherapy to relieve pain in patients with sciatica: A prospective randomized blinded clinical trial. *J Orthop Sci* 2006; 11:365-369.
20. Racz GB, Sabonghy M, Gintautas J, Kline W. Intractable pain therapy using a new type of epidural catheter. *JAMA* 1982; 248:579-580.
21. Arthur J, Racz GB, Heinrich R, Diede JH, McCann M, Wilson E, Heavner JC, Noe C. Epidural space: Identification of filling defects and lysis of adhesions in the treatment of chronic painful conditions. In: *Abstracts of the 7th World Congress on Pain.* Paris, IASP Publications, 1993: pp. 1485.
22. Manchikanti L, Pakanati R, Bakhit C, Pampati V. Role of adhesiolysis and hypertonic saline neurolysis in management of low back pain: Evaluation of modification of the Racz protocol. *Pain Digest* 1999; 9:91-96.
23. Manchikanti L, Rivera JJ, Pampati V,

Damron KS, McManus CD, Brandon DE, Wilson SR. One-day lumbar adhesiolysis and hypertonic saline neurolysis in treatment of chronic low back pain: A randomized, double-blinded trial. *Pain Physician* 2004; 7:177-186.

24. Manchikanti L, Cash KA, McManus CD, Pampati V. Assessment of effectiveness of percutaneous adhesiolysis in managing chronic low back pain secondary to lumbar central spinal canal stenosis. *Int J Med Sci* 2013; 10:50-59.
25. Park CH, Lee SH. Effectiveness of percutaneous transforaminal adhesiolysis in patients with lumbar neuroforaminal spinal stenosis. *Pain Physician* 2013; 16:E37-E43.
26. Taheri A, Khajenasiri AR, Nazemian Yazdi NA, Safari S, Sadeghi J, Hatami M. Clinical evaluation of percutaneous caudal epidural adhesiolysis with the Racz technique for low back pain due to contained disc herniation. *Anesth Pain Med* 2016; 6:e26749.
27. Manchikanti L, Singh V, Pampati V, Falco F, Hirsch JA. Comparison of the efficacy of caudal, interlaminar, and transforaminal epidural injections in managing lumbar disc herniation: Is one method superior to the other? *Korean J Pain* 2015; 28:11-21.
28. Hammer M, Doleys DM, Chung OY. Transforaminal ventral epidural adhesiolysis. *Pain Physician* 2001; 4:273-279.